National University of Ireland, Galway
Ollscoil na hÉireann, Gaillimh

15th Annual ESSR/BSSR Meeting, June 12-14, 2008

Iliopsoas Compartment Lesions

e-Poster: 1295

Congress: ESSR 2008

Type: Educational

Topic: Musculoskeletal / Soft Tissue

Authors: J.F. Costa, J. Brito, M.F..S. Seco, A. Costa, F. Caseiro-Alves; Coimbra/PT

MeSH:

Retroperitoneal Space [A01.047.025.750]

Psoas Muscles [A02.633.567.825]

Keywords: Ct, Iliopsoas compartment

1. Introduction

Learning Objectives

To review the normal anatomy of the iliopsoas compartment and to provide an overview of the multiple pathologic processes that may affect this compartment, with emphasis on the role of computed tomography.

Background

The iliopsoas muscle compartment can be involved by many different disease processes, including infection, tumor, and hemorrhage. Patients may present with a wide variety of symptoms that are often nonspecific, resulting in a delay in diagnosis. The availability of advanced imaging techniques, particularly CT, has enabled diseases affecting the iliopsoas compartment to be detected with increasing clarity.

2. Discussion

I. ANATOMY

· The iliopsoas compartment is an extraperitoneal space that extends from the posterior mediastinum to the hip joint.

· It consists of the iliopsoas and psoas minor muscles.

· The iliopsoas muscle is comprised of two muscles: the psoas major and iliacus. It is the most important flexor and pre-elevator muscle of the legs and acts also as rotator of thigh at the hip joint and as well as lateral flexor of the lower vertebral column: 1) the psoas major arises from the bodies and transverse processes of L1-4 and inserts on the lesser trochanter; 2) the iliacus originates from the fossa iliac and inserts also on the lesser trochanter.

· The psoas minor, which is absent in 40% of individuals, originates from the bodies of the T12 and L1 vertebrae and inserts on the iliopectineal eminence of the hip bone.

· All muscles in the iliopsoas compartment are covered by the iliopsoas fascia. At the superior and inferior borders, the iliopsoas fascia blends with the deep fascial planes of the chest (endothoracic fascia) and lower extremity (fascia lata), respectively.

figura1.jpg

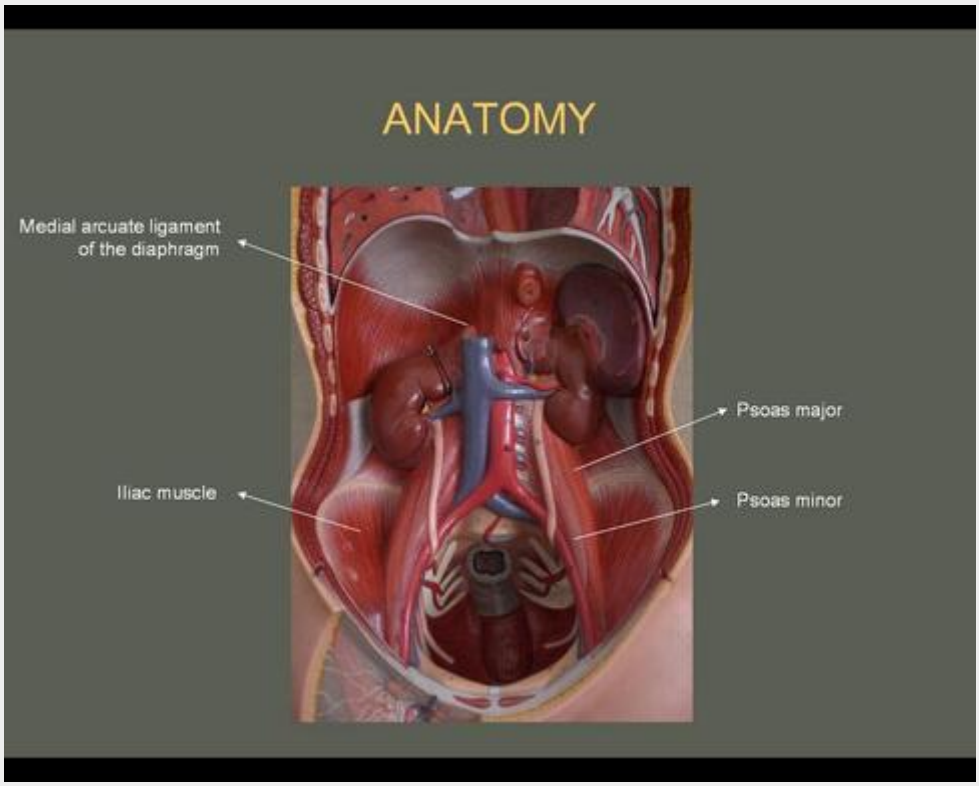

· The cranial portion of the psoas major passes into the thoracic cavity (beneath the medial arcuate ligament of the diaphragm), facilitating spread of disease into or out of the thorax via the iliopsoas compartment.

· Inferiorly, it passes beneath the inguinal ligament to insert on the lesser trochanter.

· This means that there is a conduit for the spread of pathology from the chest, abdomen, or retroperitoneum into the lower extremity.

· Anteriorly, the psoas muscle is closely related to the pancreas, aorta, inferior vena cava, and retroperitoneal lymph nodes. Structures such as the duodenum, cecum, and appendix in the right side of the abdomen and the descending colon in the left side of the abdomen are close to the iliopsoas compartment.

· Posteriorly, the psoas muscle is in contact with the posterior renal fascia and the posterior pararenal space. Because the anterior and posterior renal fascias are not always fused inferiorly, this potential opening offers a pathway for the spread of disease.

· The retroperitoneal structures are in close proximity to it. This proximity permits frequent violation of the retroperitoneal fascial planes by infection, hemorrhage, and neoplasm.

Sectional Anatomy

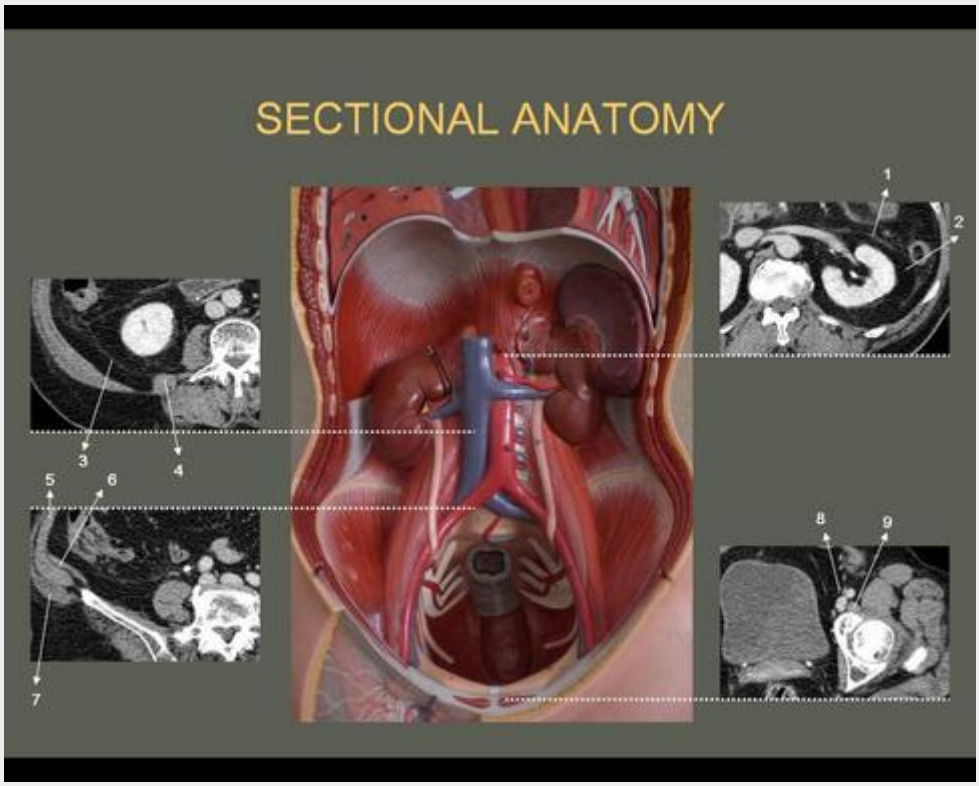

1) Anterior renal fascia; 2) Pararenal space; 3) Posterior renal fascia; 4) Quadratus lumborum muscle; 5) Internal oblique muscle; 6) Transverse abdominal muscle; 7) External oblique muscle; 8) Femoral vessels ; 9) Iliopsoas tendon

II. INTRODUCTION

· Inflammatory, hemorrhagic, and neoplastic conditions may involve the iliopsoas compartment.

· Unfortunately, it is often impossible to differentiate among tumor, abscess, and hematoma on the basis of imaging appearances alone.

· The knowledge of detailed clinical data can help improve the diagnostic accuracy, particularly with regard to primary iliopsoas lesions.

· CT is useful for delineating the source of secondary iliopsoas lesions, guiding biopsy, and performing follow-up of treated lesions.

III. INFECTION

· Primary iliopsoas abscesses are rare and are usually idiopathic.

· With the decreasing incidence of tuberculosis, the majority of psoas abscesses now encountered have a pyogenic origin. The most common organisms are Staphylococcus aureus and mixed gram-negative organisms.

· Immunocompromised patients are predisposed to primary iliopsoas infection by opportunistic organisms.

· Secondary infection of the iliopsoas muscle is much more frequent and is commonly due to direct extension from contiguous structures such as the bone, kidney, bowel (Crohn disease, appendicitis, diverticulitis), and pancreas.

· Infection may manifest as an enlargement of the iliopsoas muscle or by a low-attenuation lesion. When intravenously administered contrast material is used, ring enhancement may be seen with both CT and MR imaging.

· Secondary findings include obliteration of the surrounding fascial planes, bone destruction, and gas bubbles.

· The clinical history and knowledge of the laboratory signs of infection are important clues to diagnosis. For secondary lesions, the adjacent structure should be carefully examined to delineate the source and pathway of the spread of infection.

· Tuberculosis of the spine may extend from the vertebral bodies into the paravertebral muscles and spread along the sheath of the psoas muscle to produce psoas abscesses. Manifestations of tuberculous spondylitis that differ from those of pyogenic infections include thickening or calcification of the abscess rim, multiple abscess cavities, and minimal new bone formation.

figura3.jpg

figura4.jpg

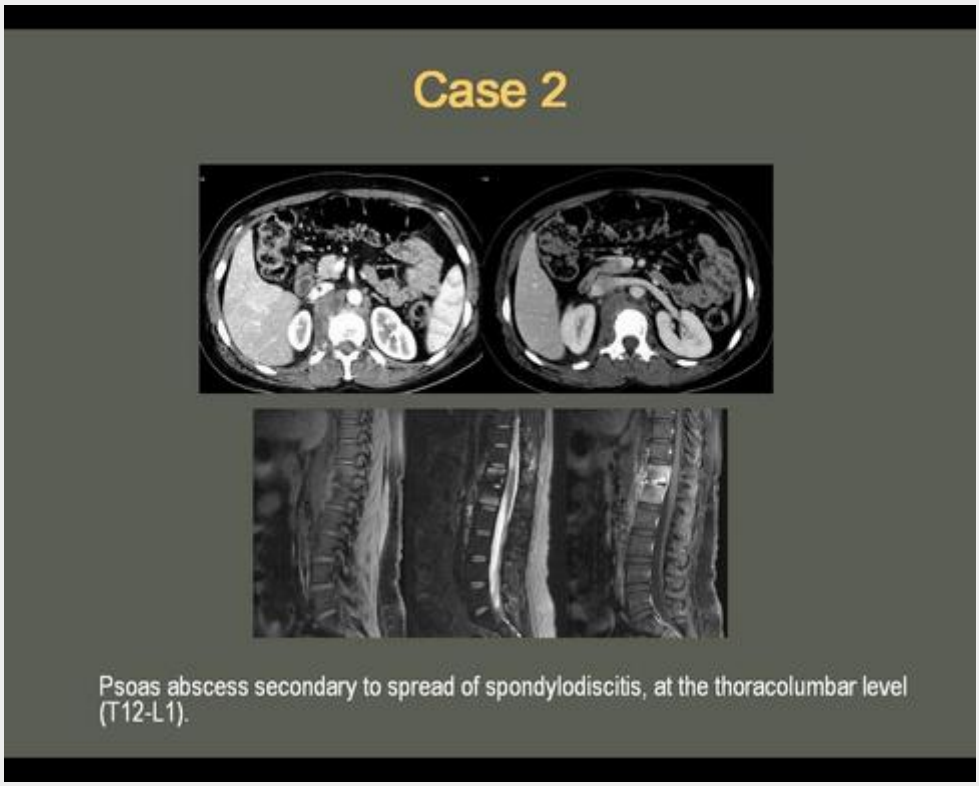

figura5.jpg

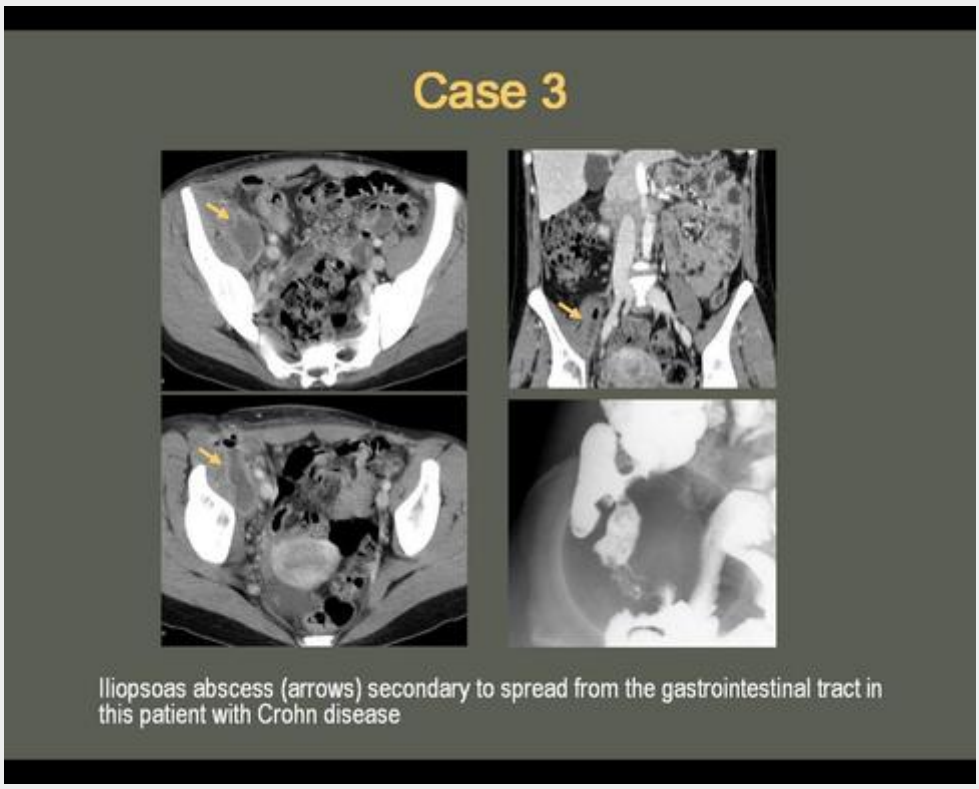

IV. HEMORRHAGE

· Primary hemorrhage into the psoas muscle can be spontaneous or may be caused by a bleeding diathesis or anticoagulant therapy.

· Hemorrhage can also be secondary to trauma, tumor, recent surgery or biopsy, inflammatory disease and extension from adjacent bleeding organs and vessels.

· Hemorrhage may infiltrate diffusely the muscle, causing enlargement or resulting in a discrete mass of high attenuation on CT scans.

· On CT scans, fresh hemorrhage is seen as a discrete mass of high attenuation. A fluid-fluid level may be present owing to the hematocrit effect.

· Chronic hematomas may be hard to distinguish from abscesses and tumors, and percutaneous aspiration may be necessary to differentiate between them.

· The MR imaging appearance of hemorrhage depends on the age of the hematoma.

· Intravenous administration of contrast material is useful for delineating ruptured vascular lesions.

figura6.jpg

figura7.jpg

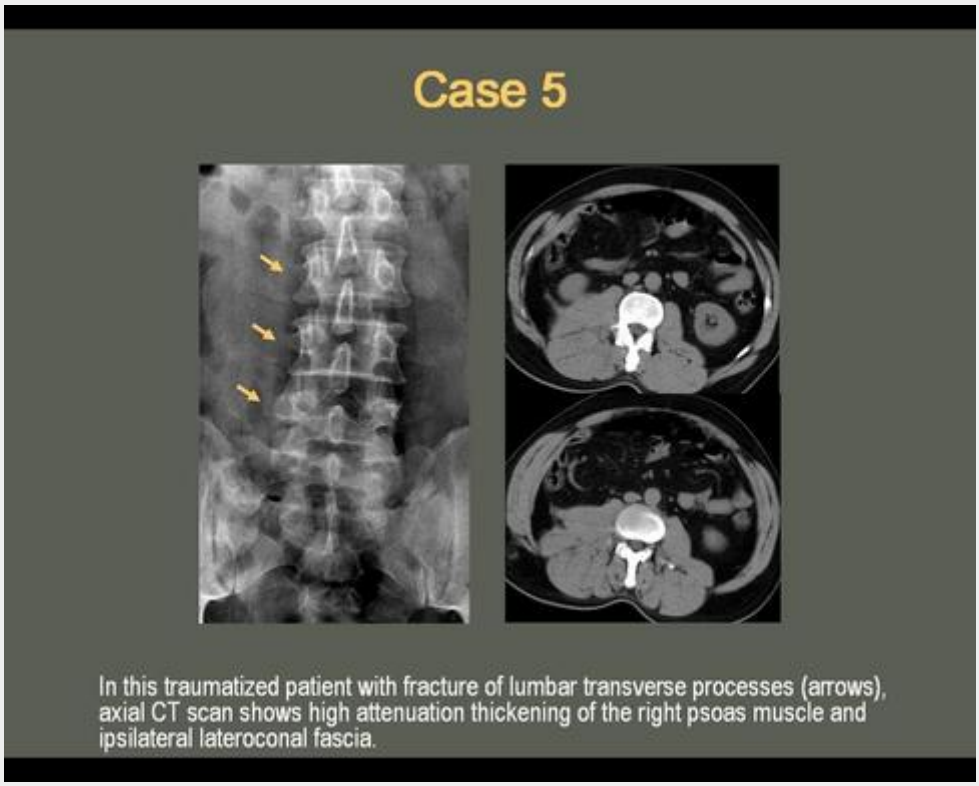

figura8.jpg

V. TUMOR

· The iliopsoas muscle may be rarely affected by primary tumors: such as liposarcoma, fibrosarcoma, leiomyosarcoma, and hemangiopericytoma.

· Neoplastic involvement of the psoas muscle is most often secondary to direct extension of primary retroperitoneal abdominal or pelvic tumors; direct invasion from adjacent lymph nodes; or hematogenous spread of malignancies such as lung cancer, breast cancer, and melanoma.

· Imaging features include enlargement of the muscle, areas of low attenuation, irregular margins, bone destruction, and retroperitoneal lymphadenopathy.

· Other features include psoas enlargement and replacement, reticulated texture, and peritumoral edema.

· Because imaging appearances are nonspecific, knowledge of the history of a known preexisting tumor is useful.

· Imaging-guided biopsy may be needed to make the diagnosis.

figura9.jpg

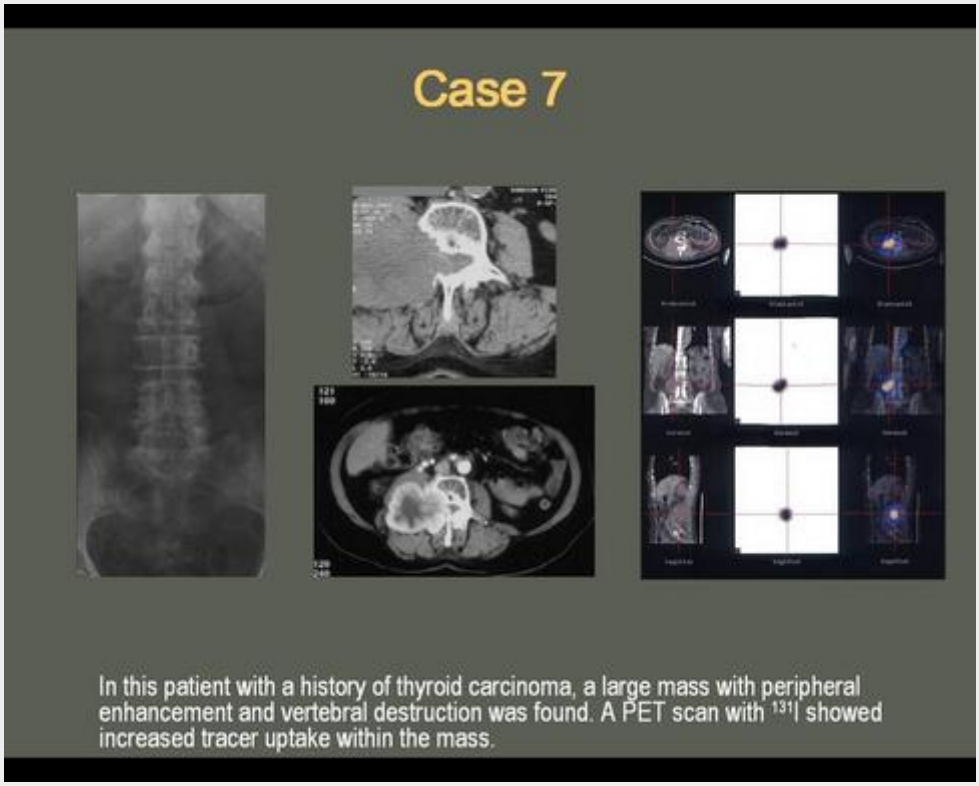

figura10.jpg

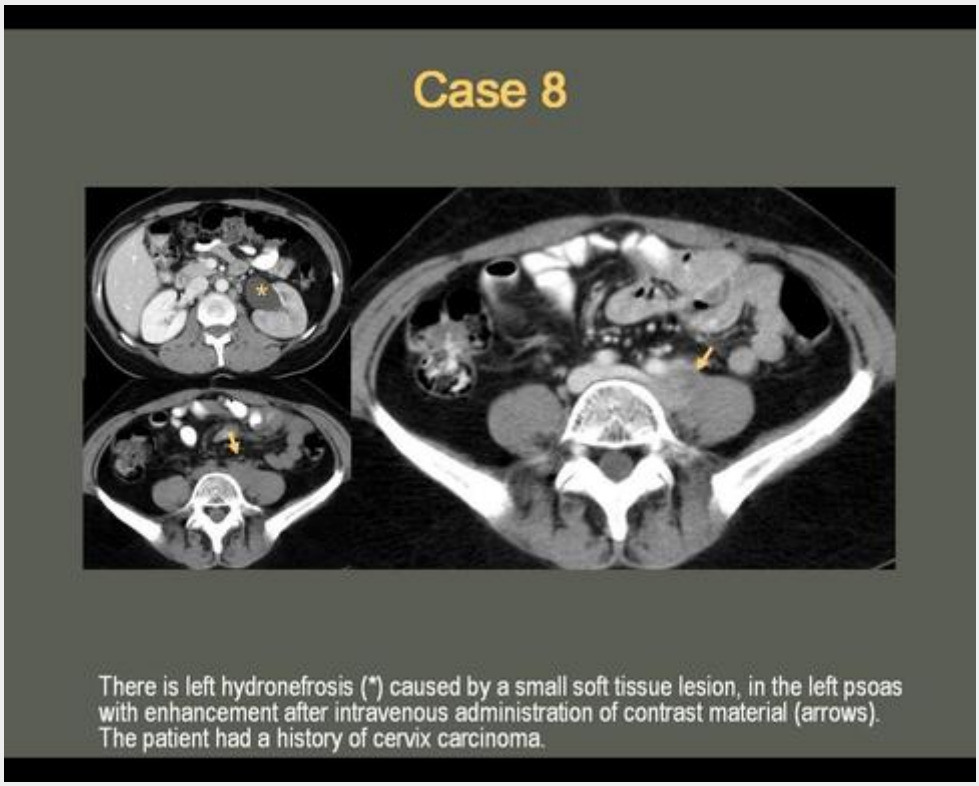

figura11.jpg

figura12.jpg

figura13.jpg

figura14.jpg

VI. MISCELLANEOUS CONDITIONS

· Atrophy secondary to paralysis or disease, muscle calcification (secondary to trauma or rhabdomyolysis) and retroperitoneal fibrosis are other conditions that may involve the iliopsoas muscle.

figura15.jpg

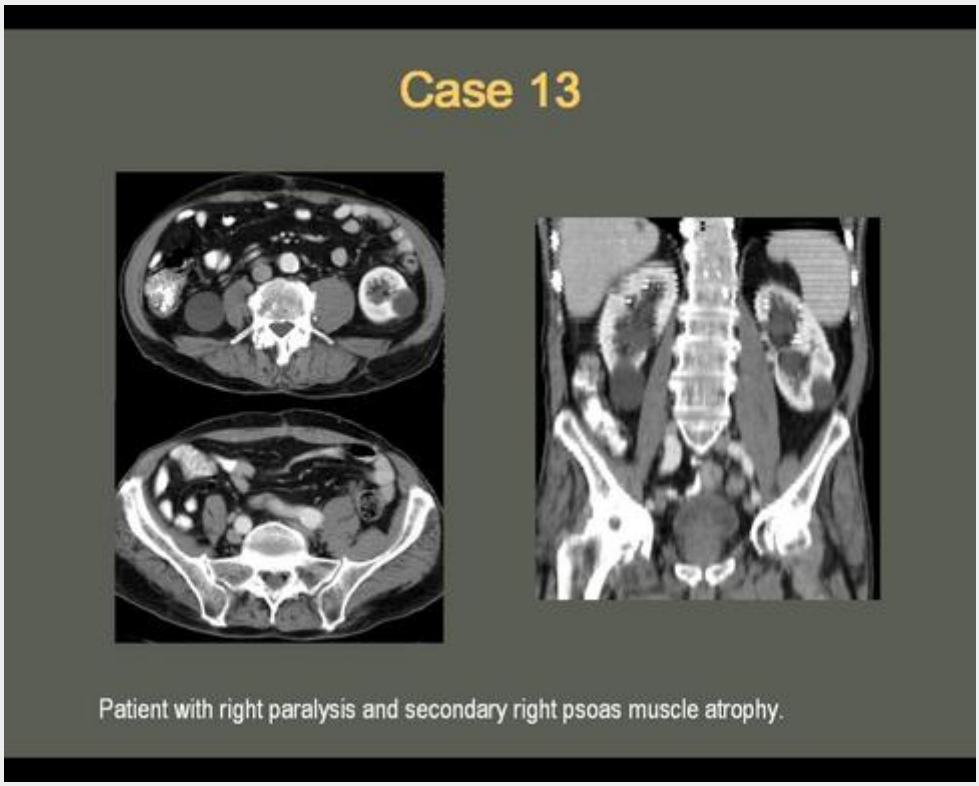

VII. CONCLUSION

· The imaging features of lesions in the iliopsoas compartment may be similar. Accurate diagnosis can be achieved with a thorough understanding of the iliopsoas compartment anatomy and its relationship to the adjacent organs combined with details of the clinical data and imaging features.

3. References

1) Review of iliopsoas anatomy and pathology; Jerrold A. Van Dyke, Howard C. Holley, Susan D. Anderson; RadioGraphics 1987 Volume 7, Number 1; 53-84

2) CT of the Iliopsoas Compartment: Value in Differentiating Tumor, Abscess, and Hematoma; Leon Lenchiki, Daniel J. Dovgan, Ruben Kier; AJR 1994;162:83-86

3) Iliopsoas Compartment: Normal Anatomy and Pathoogic Processes; Gladys M Torres, Joseph G. Cernigliaro, Patricia L. Abbitt, Patricia J Mergo, Vashti F Hellein, Steven Fernandez, Pablo R. Rós; RadioGraphics 1995; 15:1285-1297

4) CT of Unusual Iliopsoas Compartment Lesions; Malai Muttarak, Wilfred C. G. Peh; RadioGraphics 2000; 20:S53–S66

4. Mediafiles

Sectional Anatomy

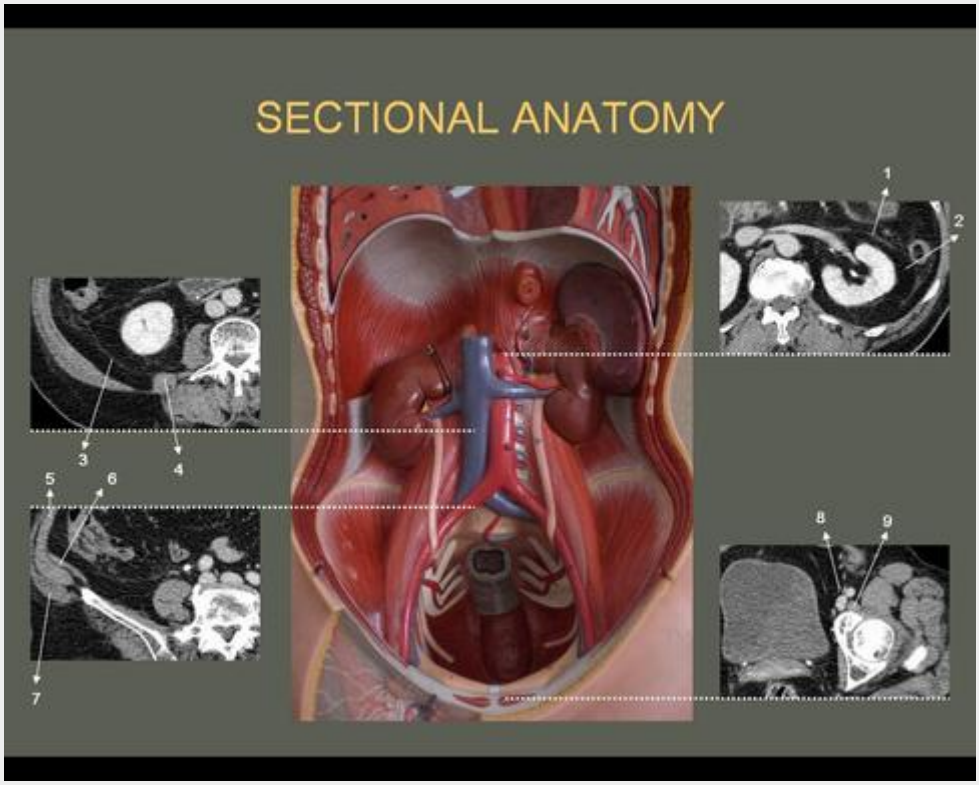

1) Anterior renal fascia; 2) Pararenal space; 3) Posterior renal fascia; 4) Quadratus lumborum muscle; 5) Internal oblique muscle; 6) Transverse abdominal muscle; 7) External oblique muscle; 8) Femoral vessels ; 9) Iliopsoas tendon

figura1.jpg

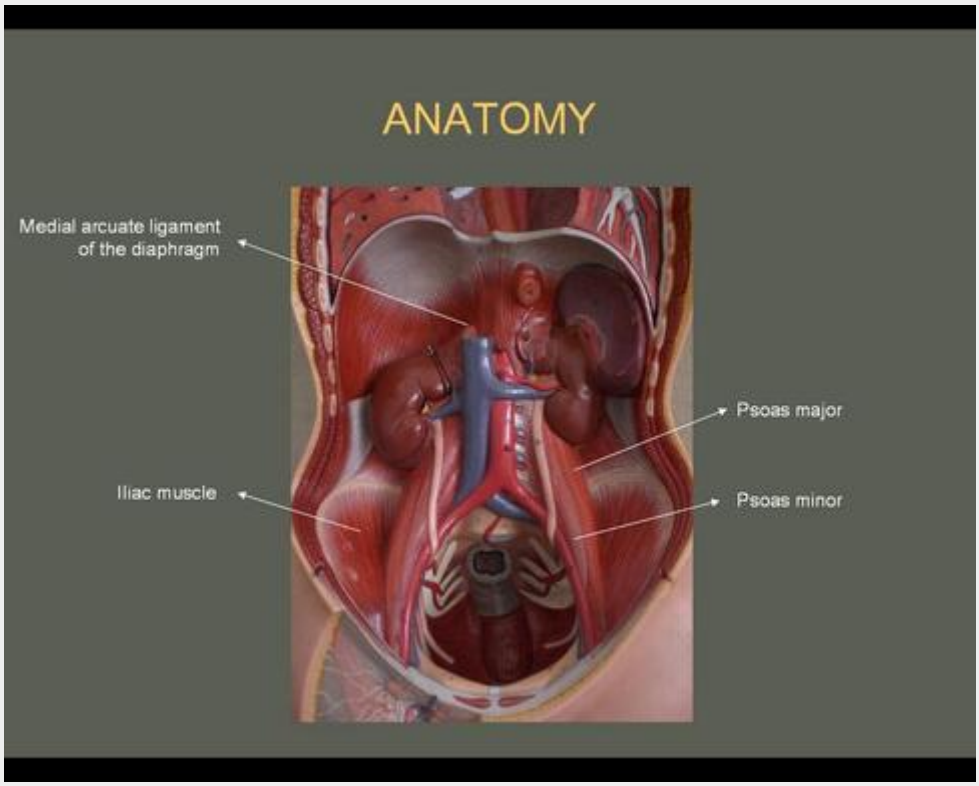

figura3.jpg

figura4.jpg

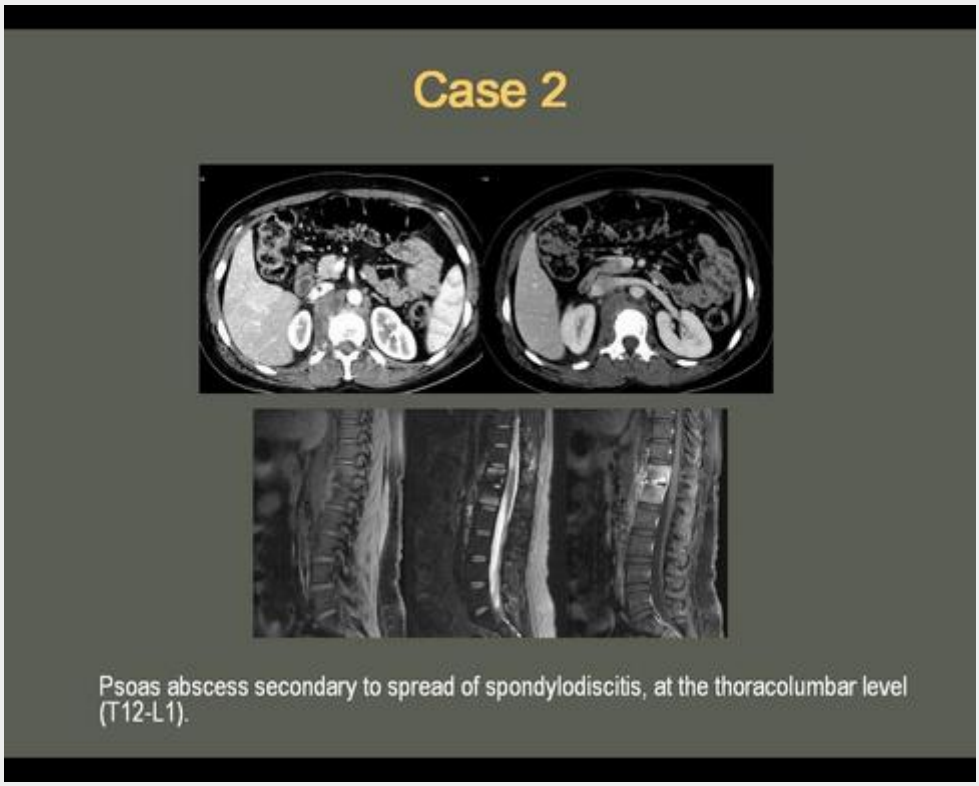

figura5.jpg

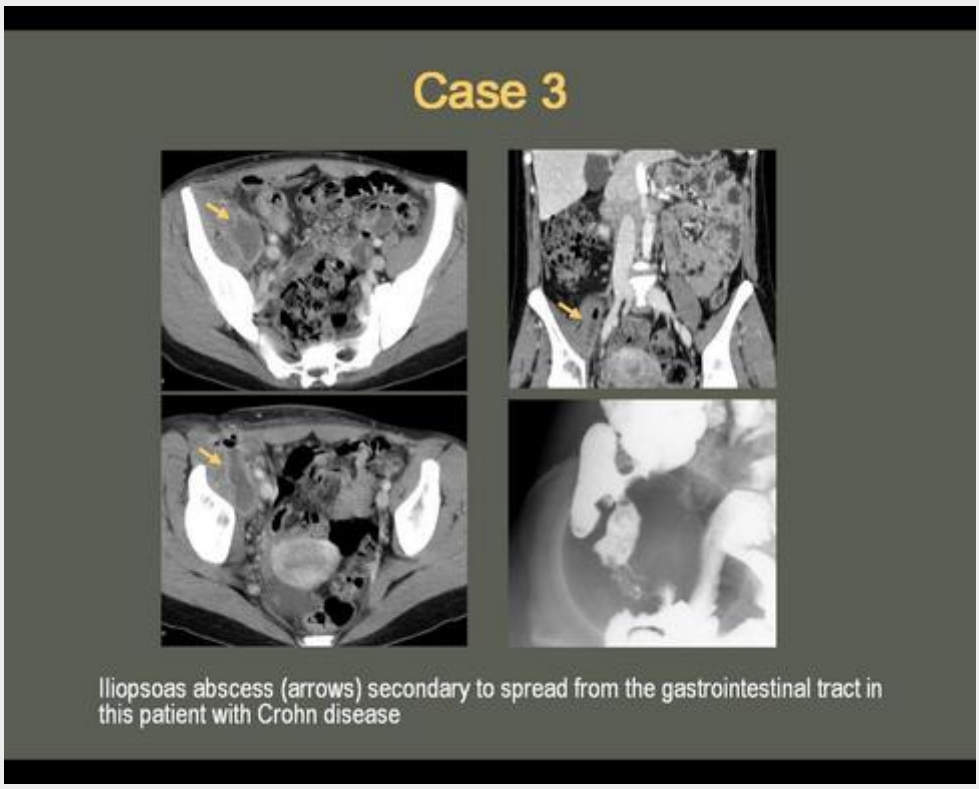

figura6.jpg

figura7.jpg

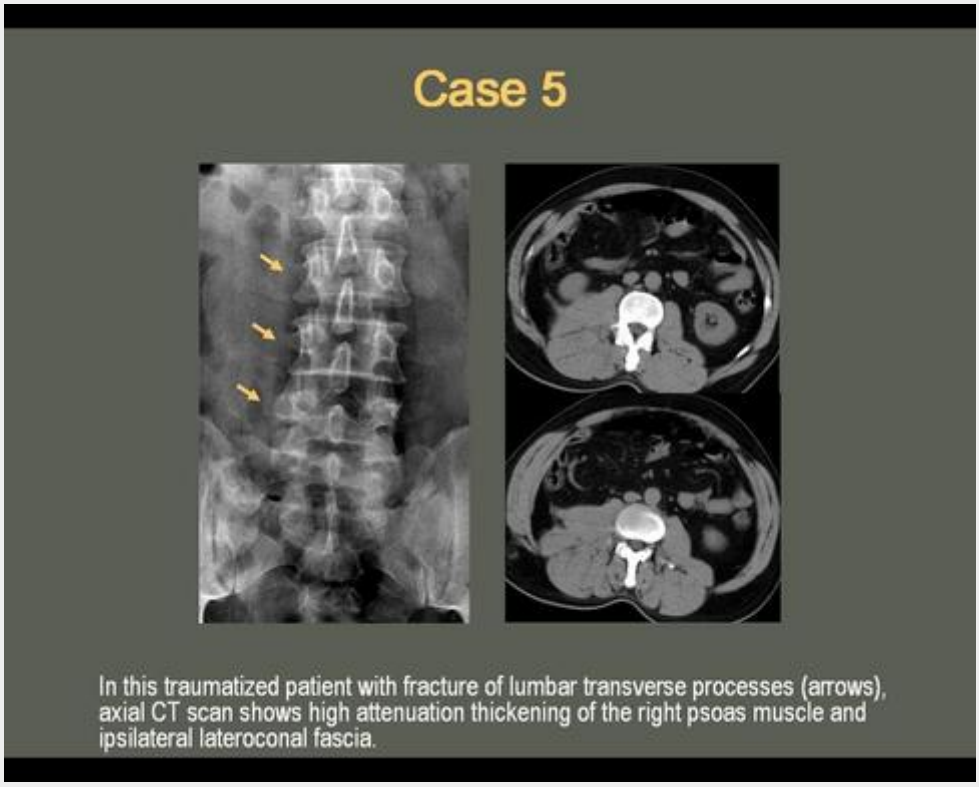

figura8.jpg

figura9.jpg

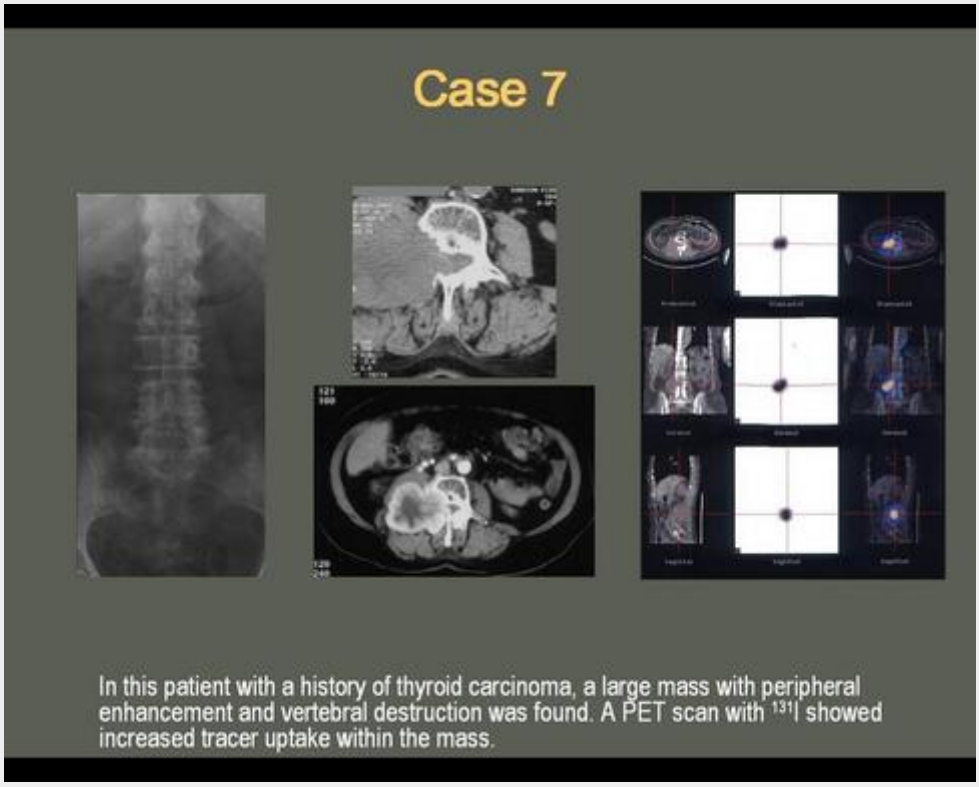

figura10.jpg

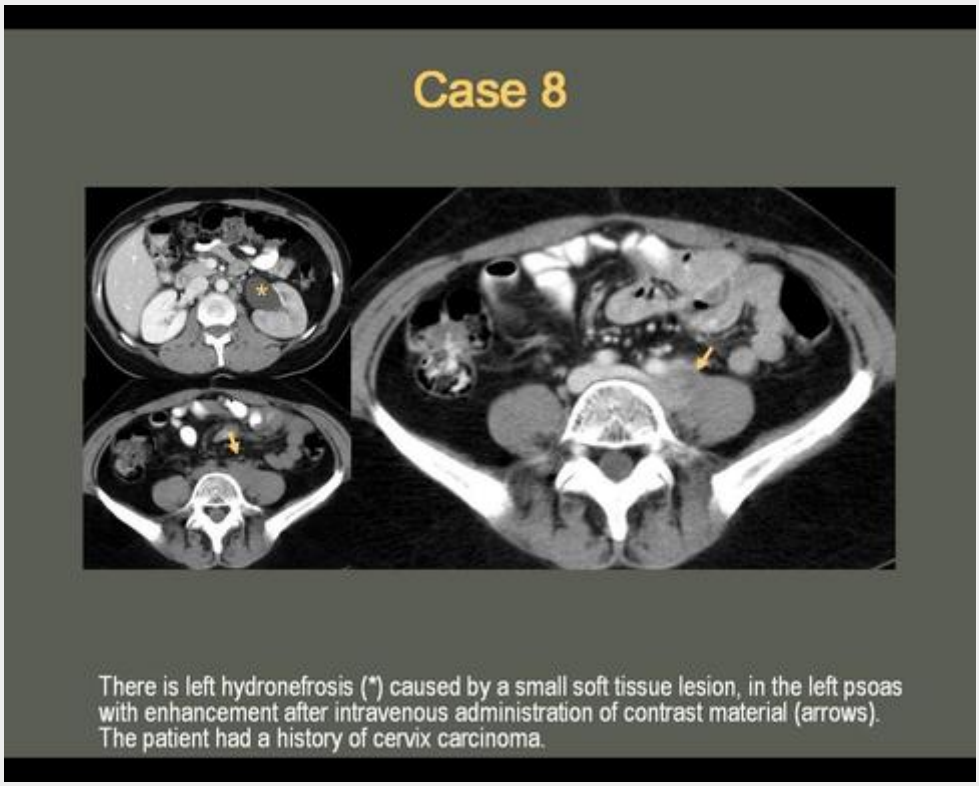

figura11.jpg

figura12.jpg

figura13.jpg

figura14.jpg

figura15.jpg